



November 2016

Published by Global Dental Implant Academy

G DIA

Dental Implant CASE REPORT

Utilization of Decalcified Autologous Tooth Block Bone and Powder Bone for Ridge Augmentation in Implant Dentistry

Part II Simplified ridge augmentation utilizing decalcified autologous particulate tooth bone graft



Dong-Seok Sohn, DDS, PhD

• Professor, Department of Dentistry and Oral and Maxillofacial Surgery, Catholic University of Daegu, Republic of Korea

Jin Y. Kim, DDS, MPH, MS, FACD*, Charles C. Park DDS**†, Grace Eun Ah Kim, DDS**††

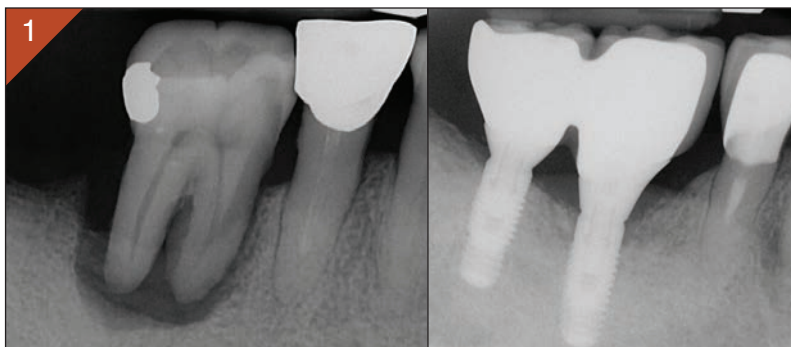


Figure 1a-b. a) Pre-operative radiograph b) 4 years post-operative radiograph

Background and Aim

Use of autogenous bone is preferred when correcting greater defects, because of its osteoinductivity when compared to other available graft materials. However harvesting autogenous bone is not favorable for the patient as it involves secondary surgery site causing greater post-operative discomfort with longer healing time and additional costs. Some other disadvantages include early exposure, potential resorption, and neurosensory disturbance. Autograft procedures also require higher level of training with experi-

ence and need to be better equipped.

Hence for some time, allogenic, xenograft, or synthetic bone materials have been alternative choices over autogenous bone grafts. Although these bone substitutes are sufficient to serve as scaffolds or spacers for volume preservation, they are only osteoconductive biomaterials. They are known to have a very slow resorption rate, and limits the newly formed bone to wholly replace the augmented ridge. In addition, the risk of cross contamination from animal and human origins are very low but cannot be disregarded.



Use of tooth derived bone graft has been recommended in the literature, to overcome disadvantages of autograft procedures.^{1,2}

Utilizing of an extracted tooth from the patient is safe, and effective in promoting regeneration of bone. Efficacy of autogenous demineralized dentine has been studied, and its similar components to human bone has shown favorable outcomes. Organic composition in dentin mainly include type 1 collagen, and various growth factors such as IGF, PDGF, FGF, TGF- β and BMP (Bone Morphogenetic Proteins) that provide scaffolding and induce bone formation.

The remaining components are non collagenous proteins including phosphoporyn, dentin matrix protein 1, and many more that trigger bone resorption and generation process.

After effective demineralization procedure, the inorganic composition of enamel can be reduced, and decalcified dentine can induce release of BMP allowing osteoinductivity.

If treated with specific acid protocols, the tooth can better retain beneficial protein contents. Without undergoing decalcification process, a crushed or grinded tooth will only have osteoconductivity, which would not have any greater benefits in regenerating bone when compared to xenograft or alloplast material.

This case report evaluates the efficacy of grafted particulate tooth bone in the extracted socket with long-term follow up.

Case Report

A 68 year old male patient visited our department requesting implant retained restorations for the lower right central incisor, and lower left lateral incisor, canine, and first molar. (Fig 2,3)

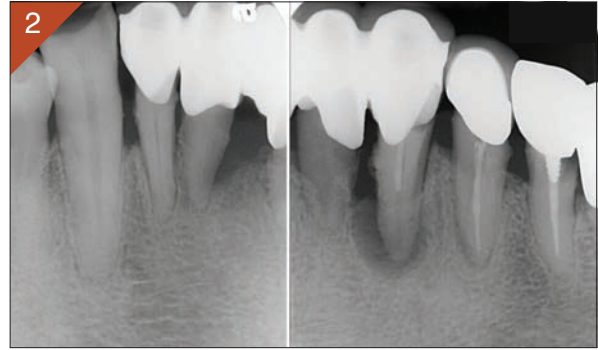


Figure 2. Severe bone resorption on the lower central incisor due to chronic periodontitis. Severe bone resorption around lower left canine due to periapical and periodontal lesion.

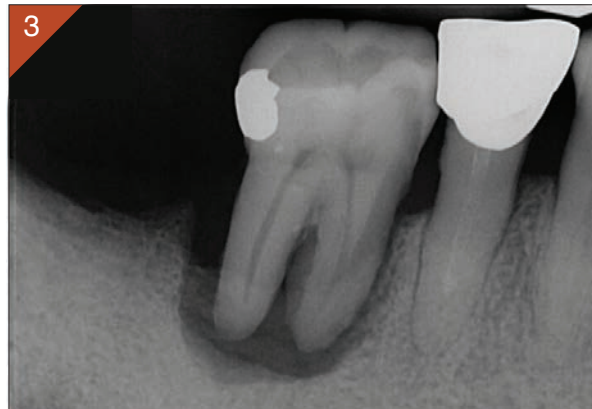

Figure 3. Severe bone resorption on lower right first molar due to chronic periodontitis.

Series of Clinical Views

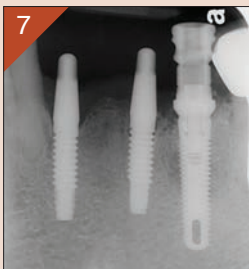

Figure 7. A postoperative radiograph.

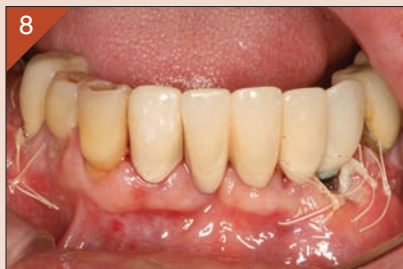

Figure 8. Immediate restoration was delivered on the next day.

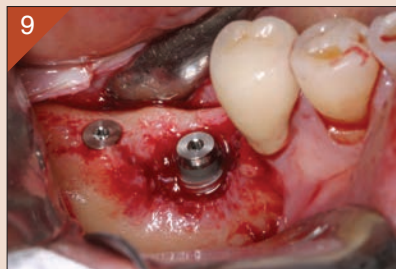

Figure 9. Severe bone defects around the molar implant.

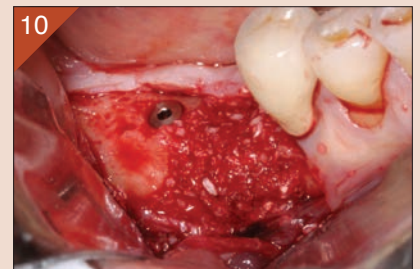


Figure 10. Sticky tooth bone is self holding, and does not require titanium mesh.

Extraction and implant surgery was performed under local anesthesia using 2% lidocaine HCl (1:80,000 epinephrine). All soft tissues adherent to the extracted teeth, pulp tissue and restorative materials were removed using a pear-shaped carbide bur. The autologous decalcified tooth graft was prepared chairside within 30 minutes for granule type and 2 hours for block type. Effective and rapid demineralisation through vacuum compression and ultrasonic vibration was made possible using the VacuaSonic® machine with specified reagents. (Cosmobiomedicare, Seoul, Republic of Korea) As mentioned in previously published journals, sticky tooth bone and concentrated growth factor (CGF) membranes were prepared, using the patient's venous blood and centrifuge machine (Medifuge®, Silfradent srl, Sofia, Italy). Inflammatory tissues in the extraction sockets were completely curetted prior to osteotomy, and apical stability of implants were achieved. Decalcified autologous tooth bone was then placed to fill any remaining socket defect, and for vertical and horizontal defects around the implants. CGF membrane was placed over the augmented ridge and secured with tension free sutures. Nonfunctional immediate provisional restorations were provided for the anterior region, but primary closure over the molar implant for two stage surgery was done.

After 4 months, all implants healed uneventfully, and the molar implant was uncovered, showing newly formed bone, and healing around the implant. (Fig 4-16)

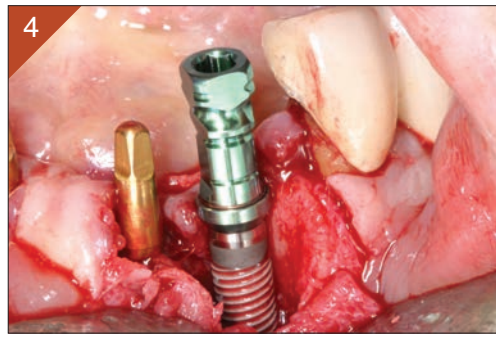


Figure 4. Apical stability of the implant was achieved but large bony defect requiring ridge augmentation is seen.

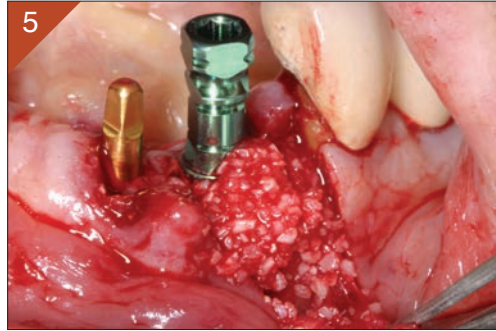


Figure 5. Sticky tooth bone graft was placed in the bony defect. The interlinked fibrin network of sticky bone prevents migration of bony particles from the graft site and enhances healing.

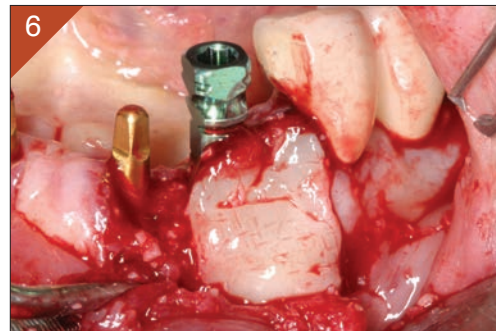


Figure 6. A layer of CGF membrane was placed over the bone graft to accelerate wound healing.

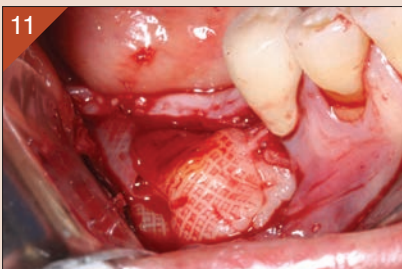


Figure 11. Two CGF membranes were placed to cover the graft to accelerate wound healing.

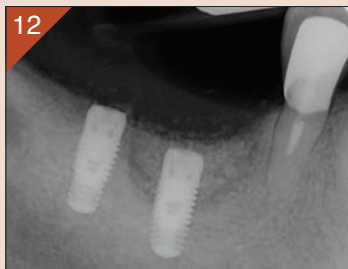

Figure 12. A postoperative radiograph showing augmented ridge with autologous tooth bone graft.

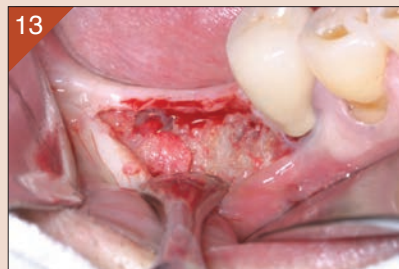

Figure 13. Successful ridge augmentation after 4 months of healing. Final restoration was delivered 4 weeks after soft tissue healing around the abutment.

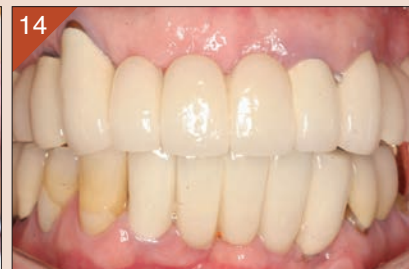

Figure 14. Final restoration after 4 years loading.

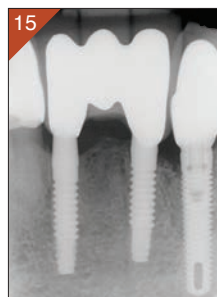

Figure 15.
A radiogram after 4 years loading shows stability of augmented ridge around implant.

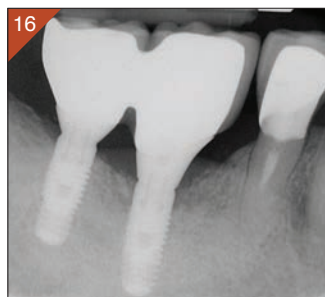

Figure 16.
A radiograph 4 years after loading at molar implant. Note stable augmented ridge.

Discussion and Conclusion

An extracted tooth from the patient can be utilized as noble bone graft material after appropriate preparation and decalcification process, in block or powder form. Chairside preparation of fresh autogenous demineralized tooth is a great alternative option over autogenous bone or other graft materials for ridge augmentation.

Favorable bone regeneration in alveolar defects have been reported clinically and histologically due to its osteoinductivity.³ As shown on this case report, fast tissue regeneration and long term stability of tooth bone assisted augmentation is achieved, with minimum morbidity to the patient, and reduced surgery and healing time.

References

1. Yeomans JD, Urist MR. Bone induction by demineralized dentine implanted into oral, osseous and muscle tissues. Arch Oral Biol 1967 12:999-1008
2. Murata M (2003). Autogenous demineralized dentin matrix for maxillary sinus augmentation in humans: the first clinical report. 81th International Association for Dental Research, Gothenburg
3. Kim ES. Autogenous fresh demineralized tooth graft prepared at chairside for dental implant. Maxillofac Plast Reconstr Surg. 2015 Feb 18;37(1):8

Correspondence

Address correspondence and reprint requests to Professor Sohn, Dong-Seok : Department of Oral & Maxillofacial Surgery, Catholic University Hospital of Daegu, 3056-6 Daemyung-4 Dong, Namgu, Daegu, Republic of Korea; E-mail: dssohn@cu.ac.kr

Acknowledgment

- * Lecturer, UCLA School of Dentistry; Private practice, Diamond Bar, California, USA
- *† Lecturer, UCLA School of Dentistry; Private practice, Denver, Colorado, USA
- ** Private practice, Brisbane, Australia



Enhancing Clinical Outcome with Natural Healing Enhancers

A One-Day Course on Clinical Applications of Autologous Blood Concentrates - PRF, CGF, AFG, Sticky Bone™ and the ASAP Protocol

Course Director



Jin Y. Kim, DDS, MPH, MS, FACD

- Diplomate, American Board of Periodontology
- Diplomate, American Board of Oral Implantology / Implant Dentistry
- Diplomate, International Congress of Oral Implantologists
- Private Practice, Diamond Bar, CA USA

Learning Objectives

- Fundamental science behind biological modifiers & human growth factors
- Historical background and development of autologous blood concentrates
- Understand the differences and commonality in PRP, PRF, CGF, AFG, BMP, and EMD
- The protocol for biologically solidified fibrin block bone preparation, popularly known as Sticky Bone™
- Clinical indications - when, where, and why
- How this approach can enhance sinus grafts, socket grafts, soft tissue grafts and ridge augmentations
- Different techniques currently used in facial rejuvenation
- The basics of phlebotomy, related anatomy, equipment and devices
- Identifying and managing complications
- Post-operative care and follow up

7 CEU



Approved PACE Program Provider
FAGD/MAGD Credit
Approval does not imply acceptance
by a state or provincial board of
dentistry or AGD endorsement
11/1/2014 to 10/31/2017
Provider ID# 352861

SELECT DATE

Nov. 19, 2016

LOCATION

La Palma, CA

TUITION

**Dentist : \$999
Auxiliary Staff : \$295***

* Limited up to 2 staffs per a dentist

To register or to contact GDIA staff
please call **323.617.4141** or email **info@gdia.com**

Copyright © Global Dental Implant Academy. All rights reserved.

Products Used

Silfradent s.r.l., Sofia, Italy

- Medifuge™

**Cosmobiomedicare,
Seoul, Korea**

- VacuaSonic®
- DecalSi-DM®



▲ VacuaSonic®





Two Days Hands-on Course on Piezoelectric Bone Surgery & Autologous Sticky Bone Augmentation Procedure



LECTURER
Prof. Dong-Seok Sohn,
DDS, MSD, PhD

This intensive two days hands-on course includes lectures, case-studies, various video demonstrations on piezo-electric bone surgery associated with dental implants. Also, it is jam packed with numerous hands-on modules including venipuncture, how to make sticky bones and CGF membranes, how to augment these bones and CGF membranes to various defective sites, learn how to immediately and successfully place implants, and learn how to lift sinus using lateral & crestal approach using the plastic models and pig skulls. These procedures including the advanced surgical techniques using piezoelectric device will be taught with unique and clinician proven step-by-step teaching.

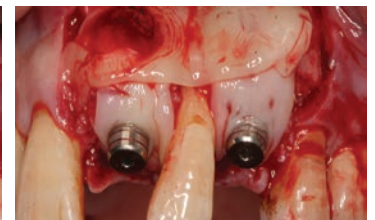
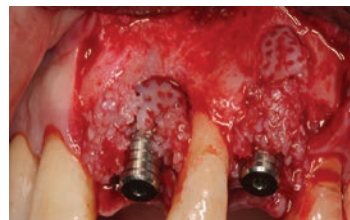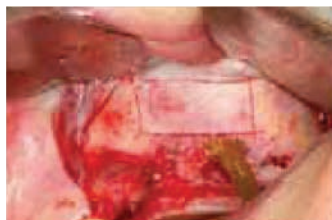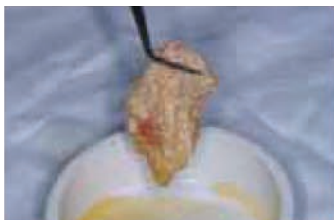SYDNEY & MELBOURNE

SYDNEY MINIMAX TRAINING CENTRE

Nov 19-20 (Sat-Sun) 2016, 9:00-17:00

MELBOURNE PARK HYATT

Nov 26-27 (Sat-Sun) 2016, 9:00-17:00



Tuition Fee : **\$3000** AUD + GST

 info@minimaximplant.com.au

 +61 2 8084 2900

 Dental Influence

GDIA Dental Implant **CASE REPORT**

November 2016
Vol. 1, No. 5



www.gdia.com



info@gdia.com